

# Inside Story HIGHLIGHTS

From the Pacific Radiology Referrer Newsletter



Pacific Radiology

## Coronary CT Angiography and Snapshot Pulse

**Imaging of the heart has always been technically challenging because of continuous cardiac motion.**

The development of ECG synchronized CT and technical improvements in CT has enabled imaging of the coronary arteries unparalleled by other non invasive imaging techniques.

Since 2006 Coronary artery CT angiography has been performed at Pacific Radio-logy with our 64 slice GE Light-Speed VCT (Volume CT).

For the detection of coronary artery stenosis in comparison to invasive coronary angiography, sensitivity ranging from 86% to 99% and specificity between 93% to 97% have been reported for 64 slice scanners.

A high negative predictive value of 95-99% suggests coronary CT angiography (CTA) has the potential to rule out coronary stenosis.

### SNAPSHOT PULSE

We have recently introduced the Snapshot Pulse technique. This new software cuts the patient x-ray dose for cardiac scans by up to 83% and we are routinely using doses of 50-70% less than previously.



The technique is based on **Prospective** gating which changes the scanner mode from conventional helical acquisition to step and shoot. The ECG gating ensures data is obtained at the *same* phase in the cardiac cycle during each slice. **Retrospective** gating acquires images *continuously* throughout the cardiac cycle while the patient is scanned with conventional helical technique.

Mean effective dose for Prospective gating is 2.8mSv which is an 83% reduction compared with Retrospective gating techniques. This is only slightly higher than background radiation in a year of 2mSv.

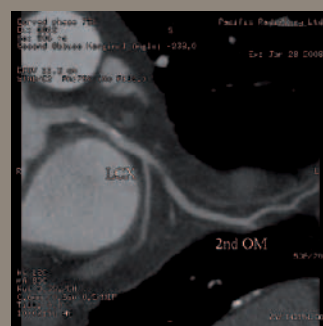
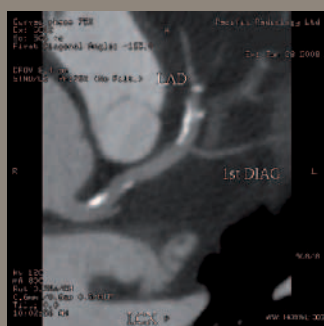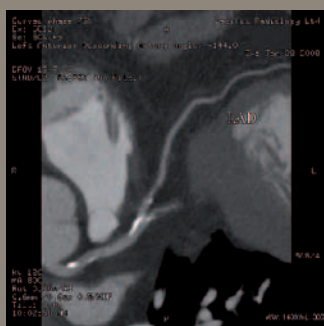
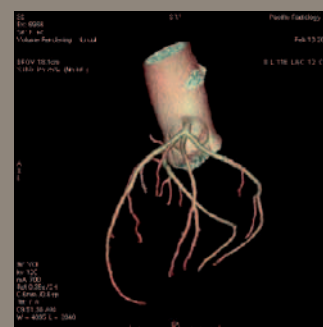
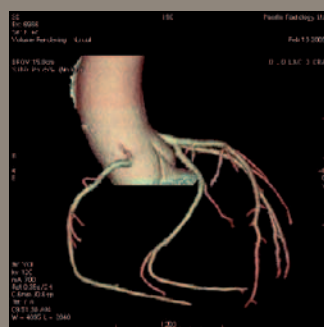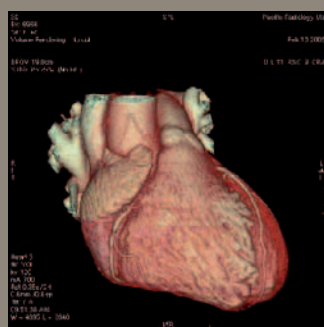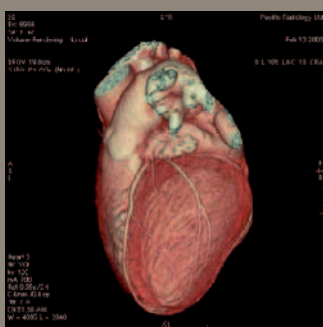Reported effective radiation dose in conventional coronary angiography ranges from 3.1 to 9.4mSv.

### CORONARY CTA INDICATIONS

These include:

- > Asymptomatic intermediate risk patients (based on Framingham risk factors);

*(continues overleaf)*



- > Atypical chest pain;
- > Stent and Bypass graft evaluation.

Coronary CTA patients are scanned in the morning after fasting avoiding caffeine, cigarettes and erectile dysfunction medication (in the 24 hours preceding the scan).

They are given a small single dose of Beta blocker (if they are not already on one) to slow and regulate the pulse to less than 70 bpm.

Patients receive prospective gating unless their heart rate is variable by more than 10 bpm when retrospective gating is used. A spray of sublingual GTN is given to vasodilate the arteries immediately prior to scanning.

The study is over for patients within 30 to 45 minutes.

Coronary CTA is an exciting and powerful technique which can now be performed on the majority of patients with a reduced radiation dose.

~ **Rodney Wu**

---

#### References

1. Prospectively Gated Transverse Coronary CT Angiography vs Retrospectively Gated Helical Technique, Earls et al. Radiology January 2008
2. Radiation Dose, Image quality, Stenosis Measurement, and CT Densitometry using ECG Triggered Coronary 64-MDCT Angiography, Horiguchi et al. American Journal of Roentgenology January 2008
3. Coronary CT Angiography, Schoepf et al. Radiology July 2007
4. Multidetector-row CT of the Heart, Schoepf et al. Radiologic Clinics of North America May 2004

