

Inside Story HIGHLIGHTS

From the Pacific Radiology Referrer Newsletter



Pacific Radiology

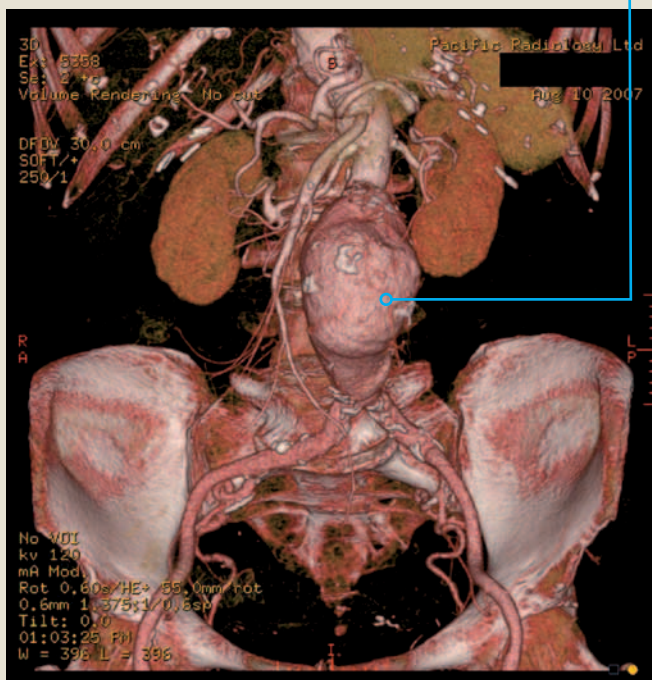
Multislice CT Scanning

Computed Tomography or CT has been around for several decades now. As a technique it has undergone a series of refinements over the years, which have greatly expanded its capabilities in patient investigation.

A CT scanner consists of a table, which the patient lies on, and a gantry with a hole in it, which is the housing for the revolving x-ray tube. The patient is examined by feeding them into the gantry in predetermined increments, while the collimated (thinly focussed) x-ray beam passes through them and the emerging attenuated x-rays are detected on the other side. Subtle differences in density of tissues within the patient are therefore displayed as different shades of grey in a pixel map of their cross section.

The holy grails of CT have been to achieve thinner slices (therefore higher resolution) and a faster examination to capture intravenous contrast as it passes through certain tissues. With successive generations of CT scanners we have now got to the point where slice thicknesses of less than 1 mm and scan speeds that can freeze- frame the beating heart have been achieved.

CT angiogram AAA showing 5.4cm infrarenal aortic aneurysm



'Spiral' scanning just refers to continuous x-ray tube rotation in the gantry, which in turn means the table can continuously feed the patient in (not like the scan /stop movements in the past) and a volume (as opposed to a slice) of data is acquired.



Mark Leadbitter

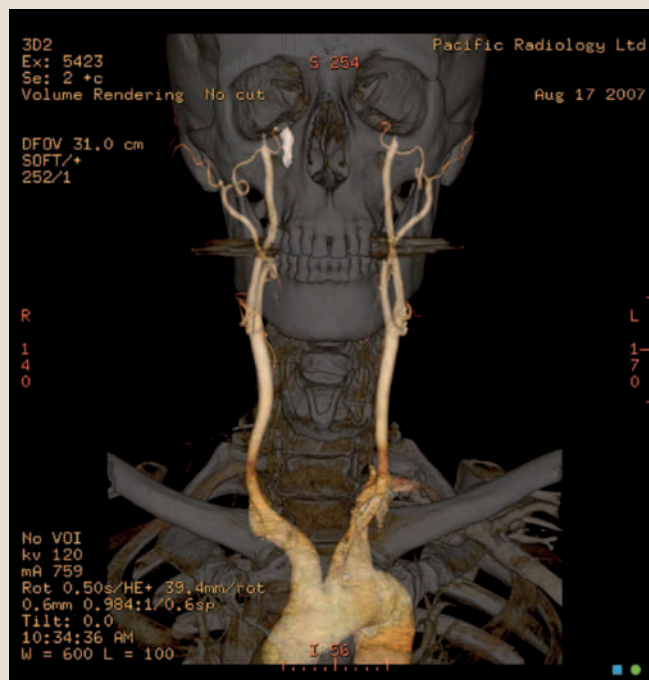
Multi-detector or multislice scanners collect more data at once, and are much faster than their predecessors. Pacific Radiology currently has 2 multislice CT scanners, the most recent of which is a 64-slice machine.

Why is there this need for speed, does it really matter? Does it just mean the scan is shorter and the patient's cup of tea is sooner?

If you give a short, power-injected intravenous bolus of contrast and you want to scan the whole chest while the contrast is still in the pulmonary arteries, there is only a short window of opportunity before the contrast has passed into the left atrium and you can no longer make out that all-important pulmonary embolus. Speed and timing are everything.

(continues overleaf)

CT arch and carotid angiogram



Also when a volume of data is acquired it can be used to reconstruct in multiple planes, giving coronal and sagittal images, which often depict the anatomy and the patient's problem in an easier to interpret way.

Multislice scanners have therefore made CT Pulmonary angiography a routine and highly accurate test, which has rapidly become the gold standard for making the diagnosis of pulmonary embolism. Feeding multislice data into 3-D workstations can produce beautiful CT angiograms of the aorta and both its central and peripheral branches. This makes much of the femoral artery puncture angiography that we used to do unnecessary, and patients much prefer the quicker CT technique, which only requires an intravenous injection.

For patients with possible peripheral vascular disease or abdominal aortic aneurysm Multislice CT angiography is usually the pre-operative investigation of choice. The speed and high resolution of the technique has also made CT coronary angiography a clinical reality for patients.

Thin slice volume acquisitions have made multiple plane spine, joint and nasal sinus reconstructions routine. Such reconstructed images can add a great deal to pre-operative orthopaedic and Endoscopic sinus surgical planning.

Multislice CT is now an everyday imaging tool available at Pacific Radiology.

~ Mark Leadbitter

